

The Use of 980-nm Diode and 1064-nm Nd:YAG Laser for Gingival Retraction in Fixed Prosthesis

Enrico F. Gherlone^a/Carlo Maiorana^b/Roberto F. Grassi^c/Riccardo Ciancaglini^d/
Francesca Cattoni^e

^a Full Professor, Chairman of Department of Dentistry; Vita-Salute University, San Raffaele Hospital, Milan, Italy. e-mail: gherlone.enrico@hsr.it

^b Associate Professor, Head of Oral Surgery and Department of Implantology, University of Milan, Milan, Italy. e-mail: carlo.maiorana@unimi.it

^c Full Professor, Periodontology and Prosthetics 1, Department of Odontostomatology and Oral Surgery, University of Bari Dental Clinic, Bari, Italy.

^d Full Professor of Clinical Gnathology, Department of Biomedical Technology, University of Milan, Milan, Italy.

^e Scientific Consultant, Department of Dentistry, Vita-Salute University, San Raffaele Hospital, Milan, Italy.

Purpose: The aim of the present study was to evaluate the tissue retraction and gingival healing in pulsed laser (diode 980 nm and Nd:YAG 1064 nm lasers) gingival retraction in comparison with the conventional mechanical or surgical techniques (double cord and electrosurgery).

Materials and Methods: A group of 103 adult patients, 45 women, 58 men (mean age 42, range 19 to 52 years) scheduled for fixed and implant prosthetic rehabilitation was recruited, and four impression techniques were compared: the double cord technique, the electrosurgery technique, the 980-nm diode and the 1064-nm Nd:YAG laser technique. Patient were randomly placed into four groups according to impression-taking technique. Thirty impressions were taken in each group, for a total of 110 elements each. The preferred impression materials were addition silicones (polyvinyl siloxanes) (2nd generation). The outcome was measured by the bleeding index (during the impression taking and after 15 days) and gingival retraction (after 15 and 30 days).

Results: Compared to the conventional techniques, both laser techniques proved to be less aggressive in terms of absence of gingival bleeding (99.2% vs 92.7%). There were also fewer cases of gingival retraction than with the conventional technique (2.2% vs 10%).

Conclusion: This study suggests that the laser technique can be valuable for implant prosthetic rehabilitation. While both the conventional and laser techniques are satisfactory in achieving gingival retraction, the laser techniques may be less traumatic to the periodontal tissue.

Key words: impression techniques, diode 980 nm laser, Nd:YAG laser, electrosurgery, polyvinyl siloxanes, gingival retraction, oral soft tissue surgery.

J Oral Laser Applications 2004; 4: 183-190.

Submitted for publication: 23.04.04.; accepted for publication: 16.07.04.

In recent years, the clinical applications in dental prosthetics have undergone protocol changes regarding the new technologies and methods made available by scientific research. Impression taking is an important technical step in the overall procedure of creating a successful prosthetic object.¹ Because of the enormous

variability of clinical cases, it is not possible to use a single method or impression material for fixed prostheses and therefore each operator is confronted with numerous techniques – both conventional and innovative – and must be able to adapt the most suitable one to the specific clinical case.

In order to obtain correct retraction of the gingival margins, the ideal condition is a state of optimum periodontal health, ascertained in advance.^{2,3} However, each operator must deal with the risk of gingival recession, a major problem which may cause work delays or even functional and esthetic failure, meaning the prosthesis must be re-made.⁴⁻⁶

Lasers first began to be used for prosthetic applications just in the last few years,⁷ and their application on gingival tissue was made possible particularly by the use of flexible optical fibers (the most commonly used diameters range from 320 to 400 microns for prosthetic applications), ensuring high precision of laser action at the crevicular sulcus level. Sulcus conditioning with laser is an innovative method in the process of restoration with a fixed prosthesis, and the ever-increasing operator interest in its atraumatic properties has made its development possible.⁷

In the medical field, diode lasers are widely used in many areas, from diagnostics to surgical applications.⁹⁻¹¹ The diode laser, with 980-nm infrared emission, was introduced in the medical field during the last decade on account of its specific wavelength, which allows treatment of oral cavity soft tissues with optimum cutting and coagulation properties.^{9,10}

The active medium of the Nd:YAG laser is an yttrium-aluminum-garnet core, doped with neodymium, which was introduced in the dental field during the early 80s.⁸ It is used in many medical areas for soft tissue surgery.

Given this background, the aim of the present study was to evaluate the tissue retraction and gingival healing using pulsed laser (980-nm diode and 1064-nm Nd:YAG) gingival retraction, in order to assess the clinical non-invasiveness of this technique in comparison with the two standard conventional techniques of double cord and electrosurgery.

MATERIALS AND METHODS

During the period from January to December 2002, a sample of 103 consecutive adult patients, aged 19 to 57 years (mean 42 ± 9 years), was recruited for the study at the Oral Rehabilitation Service of the San Raffaele Hospital (Milan). All the patients underwent prosthetic and implant prosthetic rehabilitation of the anterior and posterior dentition. Patients with pacemakers or severe systemic diseases were excluded from the study.

Before starting prosthetic treatment, the patients' periodontal status was examined according to the Loe

index¹² in order to determine the degree of periodontal inflammation, and according to the periodontal treatment need index introduced by Ainamo.¹³ Briefly, the Loe index is defined as follows: 0, total absence of gingival inflammation; 1, slight variation of tissue color and form; 2, evident inflammation and bleeding tendency upon probing; 3, evident inflammation and spontaneous bleeding. The Ainamo score index is defined as follows: 1, absence of pockets and absence of calculus/slight bleeding upon probing; 2, pockets < 3 mm, calculus and subgingival plaque; 3, pockets > 4 to 5 mm; 4, pockets > 6 mm.

Based on the Loe and Ainamo indices the patients underwent the following therapy: no therapy (n = 31), scaling (n = 46), supra- and subgingival scaling (n = 26), more complex treatment (n = 0). Scaling was performed using ultrasound as well as manual instruments (Gracey curettes 5/6, 7/8, 11/12, 13/14, MEDCO Instruments, Crestwood, USA).

Patients were randomly allocated to four groups with respect to the technique used for gingival retraction. Randomization was performed in blocks of 10 patients according to the location (anterior or posterior) of the impression. The assessed techniques were retraction cord (A), sulcus conditioning with electrosurgery (B), sulcus conditioning with 980-nm diode laser (C), or sulcus conditioning with Nd:YAG laser (D). For each technique, 30 impressions were taken: 20 impressions of 3 anterior elements and 10 of 5 posterior elements. The prosthetic phase was thus carried out on a total of 440 dental elements. At the end of the preparation, the elements were temporarily treated with resin products, cold relined with Dura Lay (Kerr, Romulus, MI, USA), and then finished to stereoscopically ideal conditions.

The impression materials used were addition silicones (polyvinyl siloxanes, 2nd generation), and elastic hydrophobic materials (heavy: high-viscosity polyvinyl siloxane; light: low-viscosity polyvinyl siloxane). The two-phase method (putty-wash) was employed.^{14,15} Protocols described in the literature were carefully followed. Before an impression was taken, plexus anesthesia with 4% articaine and 1:100,000 adrenaline (Ubistein 4%, ESPE, Seefeld, Germany) was performed.

Impression Technique with Retraction Cords

Two cotton fibers of different diameter are used inside the sulcus before taking the impression, paying particular attention to the force applied in packing the retrac-

tion cords. The first cord has a smaller diameter than the second and is inserted into the gingival sulcus and positioned in the undercut, while the other is inserted closer to the surface and is then removed, according to the protocol during the relining of the impression itself.^{16,17}

Sulcus Conditioning with Electrosurgery

An electrotome (Dento-Surg 90 FFP, Ellmann International, Oceanside, NY, USA) was applied using only the cutting current. The point of a thin electrode was inserted under the preparation margin at an angle of 30 and 45 degrees with reference to the tooth axis, opening the sulcus with a circular movement around the dental element. Then the protocol required preparing the element toward the apical for 0.1 to 0.3 mm to balance the obtained gingival retraction.^{18,19}

Laser Techniques

The types of laser used in this study were a semi-conductor or diode laser with a wavelength of 980 nm (Dio-Dent, Wintek, Caesarea, Israel) and a solid-state laser, the Nd:YAG (Pulse Master 600 IQ, American Dental Technology, Corpus Cristi, TX, USA). Optical fibers with a diameter of 320 to 400 microns were used according to the following protocol: diode laser 980 nm, 2.5 to 3.5 W/CW; Nd:YAG laser, 2.5 to 4.0 W, 25 to 40 Hz, 100 mJ. The optical fiber was inserted inside the crevicular sulcus to a depth of 1.0 to 1.5 mm, and a circular movement was made around the dental axis for 15 to 20 s.

After impression was taken, the patient was instructed to use a mouthwash containing 0.2% chlorhexidine for the following seven days.

The investigated outcome parameters were the short-term gingival recession at 15 and 30 days postoperatively (always evaluated by the same operator unaware of the impression technique used) measured with a periodontal probe, and the bleeding index, evaluated just after the taking of the impression and 15 days later.

Statistical Analysis

Descriptive data are reported as the number of observations or percentage. Comparison within and between groups was performed with the chi-square test

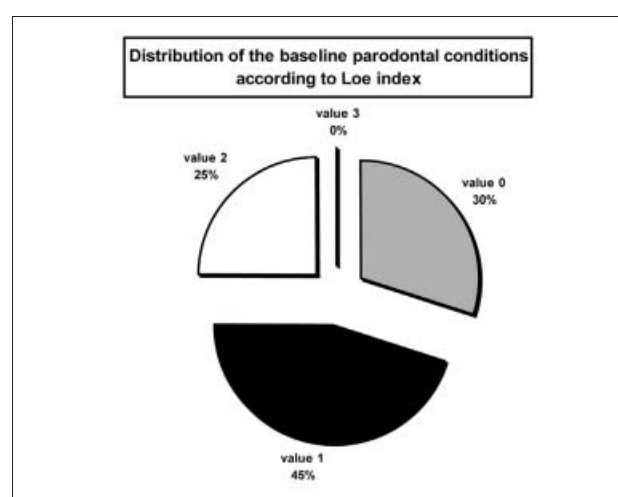


Fig 1 Distribution of the baseline periodontal status according to the Loe index.

or the Fisher's exact test, as appropriate. Significance of multiple comparisons was adjusted by the Bonferroni correction. All p values < 0.05 were considered to indicate statistical significance (two-tailed test).

RESULTS

Figure 1 depicts the baseline periodontal status as assessed by the Loe index. No difference occurred among groups with respect to the distribution of the Loe index or therapy.

Figure 2 shows the distribution of the number of gingival recessions in the four groups at 15 days: 7.3% for the double-cord technique, 12.7% for the electrosurgery technique, 1.8% for the 980-nm diode laser technique, and 2.7% for the Nd:YAG laser technique. At 30 days, only one gingival recession was observed on an anterior element in the double-cord group (45-yr-old female, dental element 13).

Significantly fewer recessions were observed in the laser groups as a whole (5 out of 220) vs the conventional technique groups (22 out of 220) ($p = 0.002$). No significant difference occurred between the two laser techniques or between the two conventional techniques. Tables 1 and 2 show the distribution of the gingival recessions by dental area at 15 days and at 30 days, respectively.

Figure 3 shows the distribution of the gingival bleeding by group that occurred during impression taking: 14.5% for technique A, 3.6% for technique D, and no

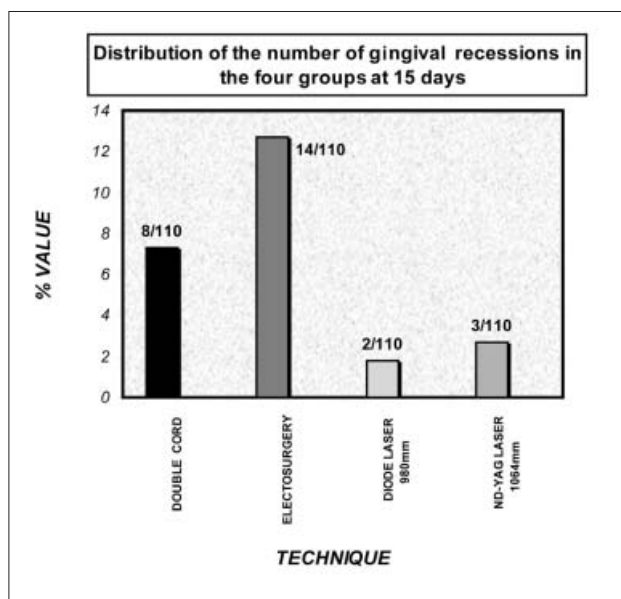


Fig 2 Distribution of the number of gingival recessions in the four groups at 15 days.

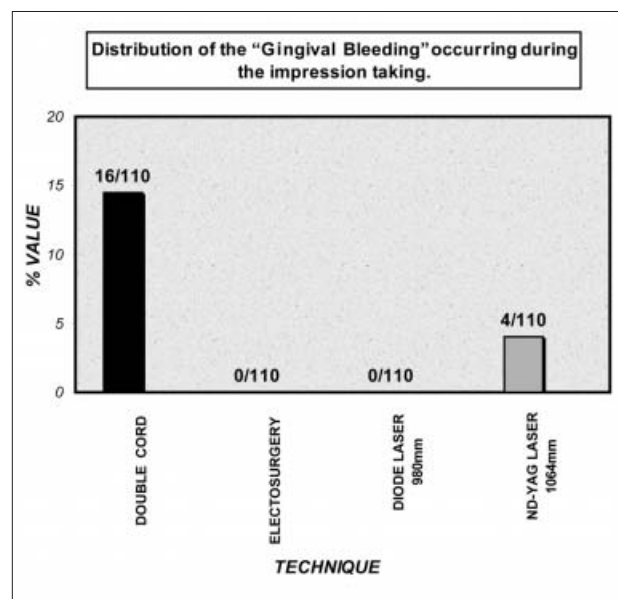


Fig 3 Distribution of gingival bleeding during impression taking.

bleeding for techniques B and C. At 15 days no instance of bleeding was observed for any of the investigated techniques. Table 3 shows the distribution of gingival bleeding by dental area during treatment.

DISCUSSION

The aim of this study was to clinically evaluate four techniques relative to impression taking in fixed prostheses in order to compare their traumaticity to the periodontal tissues, and in terms of establishing the preparation margin of the treated dental elements, while simultaneously limiting the cases of gingival recession.

Gingival recession was investigated because its occurrence can cause the failure of the operating procedure (Fig 4), consequently requiring re-preparation towards the apical of the dental element and the repetition of the impression taking step.⁴⁻⁶

In the present study, the laser techniques were capable of correctly conditioning the crevicular sulcus, both in terms of vertical and horizontal dilation (more easily obtained using the diode than the Nd:YAG laser), yielding a correct reading of the preparation end line, which kept the invasiveness into the periodontal structures to a minimum (Fig 5).

The laser techniques have also been proven to be valid in patients with gingival bleeding tendencies, and efficient in terms of treatment speed and patient acceptance due to low invasiveness and lack of pain.⁹⁻¹¹

In this study, an advantage noticed using laser techniques was the less aggressive effect on the periodontal tissues (Fig 2). Moreover, plexus anesthesia by infiltration was not always necessary; treatment time was lower, and it was possible to obtain hemostasis in patients with a hematic exudation tendency using the diode laser (Fig 3).

The main disadvantages essentially consist of a smaller horizontal opening of the sulcus noticed with the Nd:YAG laser (tendency to tear off material beyond the finishing line, if natural undercuts are present), and higher operating costs.

The conventional double-cord technique yielded a correct reading of the margins of the dental preparation (Fig 6) and lower operating costs. However, the major clinical disadvantage was a relatively high incidence of recessions, particularly in the anterior area, and a higher tendency to bleeding in comparison with laser techniques (Fig 3). Moreover, the execution of the technique is rather complex.

The advantages of the electrosurgery technique are good execution speed, low costs, and optimum coagulation (immediate bleeding index = 0), while a relevant

Table 1 Distribution of the number of gingival recessions by dental area and technique at 15 days

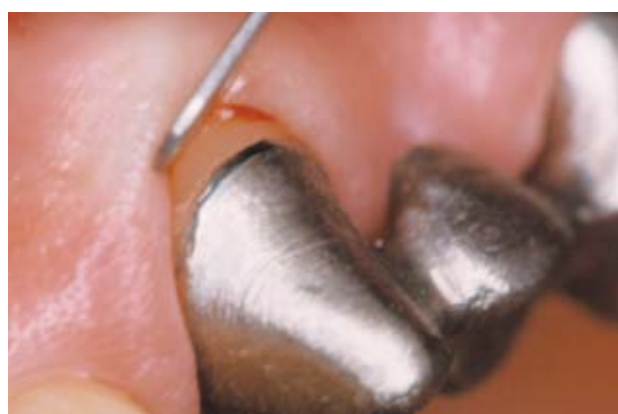Technique	Anterior teeth	Posterior teeth
A (double cord)	5/110	3/110
B (electrosurgery)	9/110	5/110
C (980-nm diode laser)	1/110	1/110
D (1064-nm Nd:YAG laser)	2/110	1/110

Table 2 Distribution of the number of gingival recessions according by dental area and technique at 30 days

Technique	Anterior teeth	Posterior teeth
A (double cord)	1/110	0/110
B (electrosurgery)	0/110	0/110
C (980-nm diode laser)	0/110	0/110
D (1064-nm Nd:YAG laser)	0/110	0/110

Table 3 Distribution of gingival bleeding during treatment by treated dental area

Technique	Anterior teeth	Posterior teeth
A (double cord)	9/110	7/110
B (electrosurgery)	0/110	0/110
C (980-nm diode laser)	0/110	0/110
D (1064-nm Nd:YAG laser)	3/110	1/110

**Fig 4** Gingival recession (male, 53 years old, anterior dental arch)

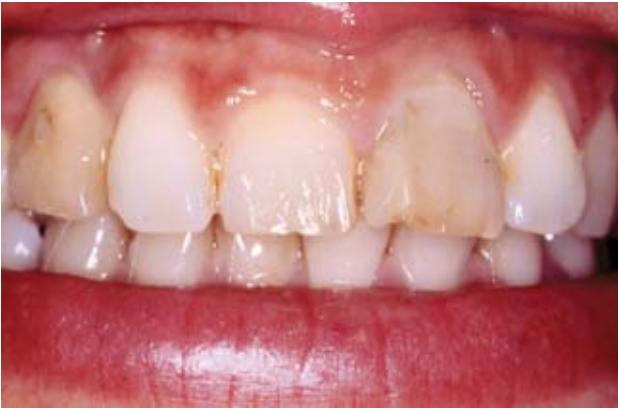

Fig 5a Initial clinical case (female, 39 years old, anterior elements).

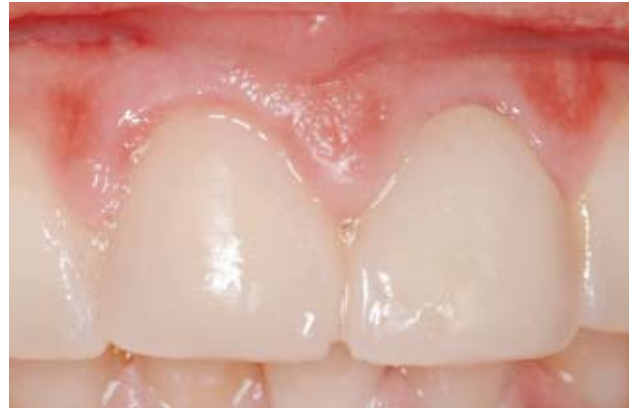

Fig 5b Temporary crown cold relined with Dura Lay.

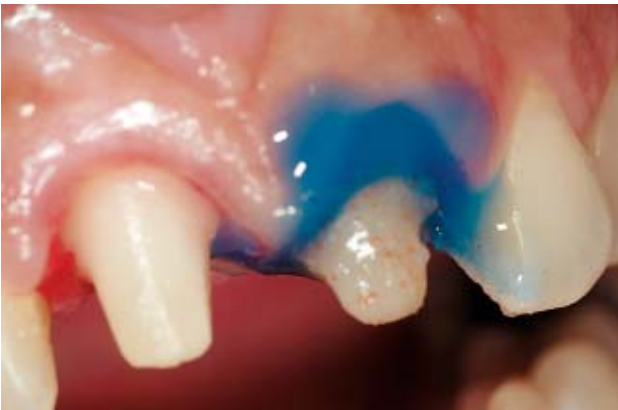

Fig 5c Bleaching of dental element with diode laser.

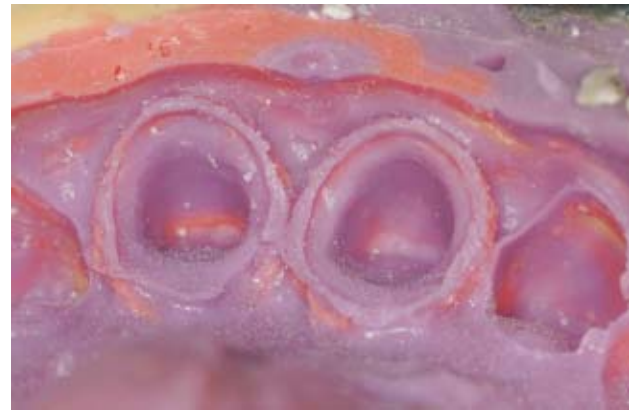

Fig 5d Correct conditioning of crevicular sulcus with the 980-nm diode laser technique.

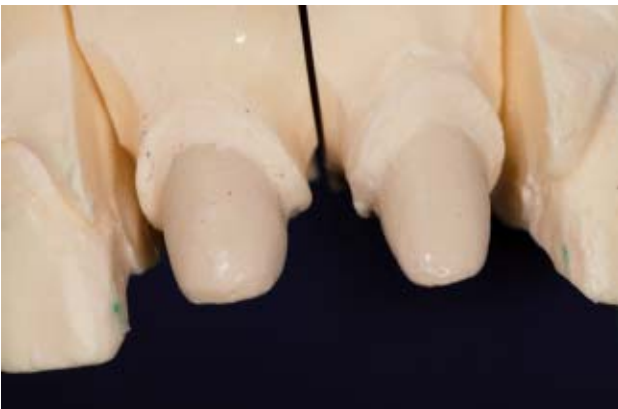

Fig 5e Master Model: the correct reading of the preparation end line.

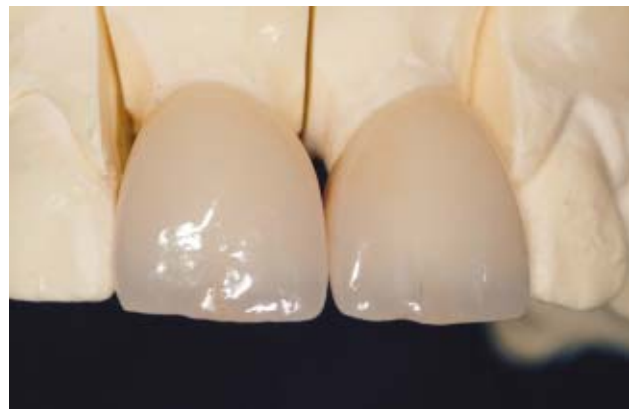

Fig 5f Buccal view: metal-free jacket crown positioned on Master Model.

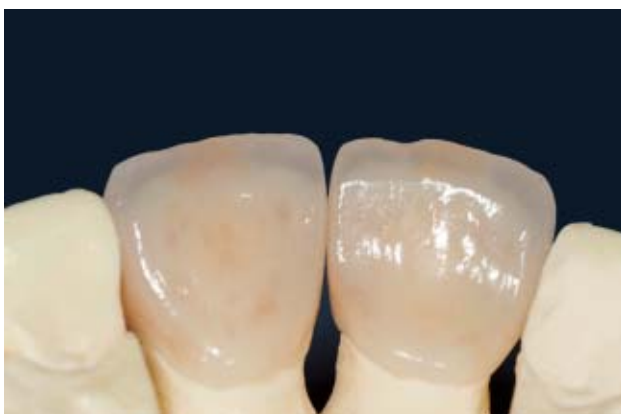

Fig 5g Palatal view: metal-free jacket crown positioned on Master Model.

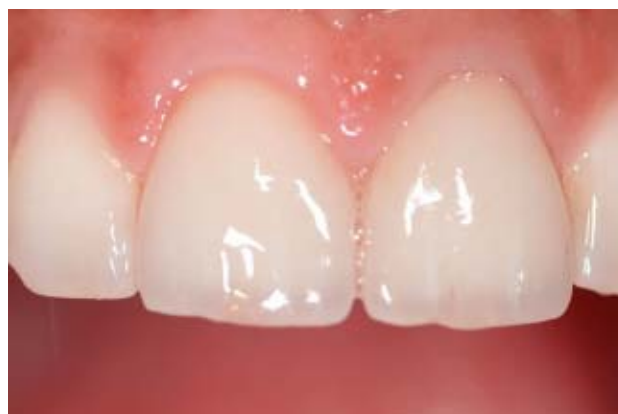

Fig 5h Jacket crown: cemented, buccal view.

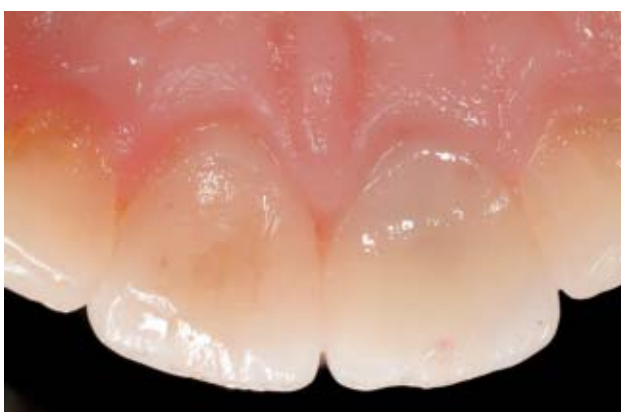

Fig 5i Jacket crown: cemented, palatal view.

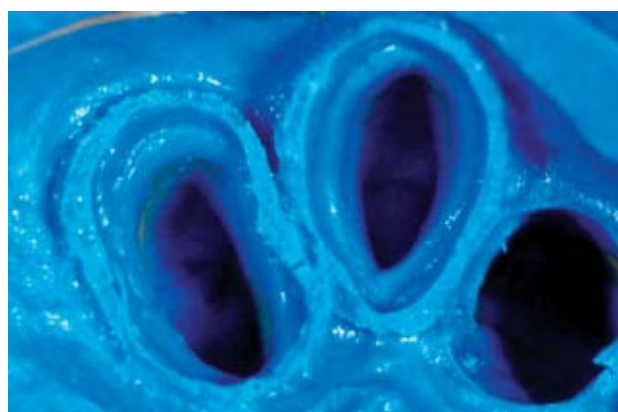


Fig 6 Correct reading of the margins of dental preparation with conventional double cord technique (male, 52 years old, anterior dental arch).

clinical disadvantage is the high short-term incidence of recession (Fig 7).

CONCLUSION

This study highlighted the lower traumaticity of the laser-assisted sulcus conditioning (980-nm diode and Nd:YAG) on the periodontal structures, as compared with conventional (mechanical and surgical) techniques. Based on the present results, it can be concluded that the laser can be a valuable tool for obtaining anatomical information for fixed prostheses, and it is capable of yielding correct results with maximum respect for the anatomy of the oral tissue. In addition, during impression taking, 980-nm diode laser may exhibit a higher hemostatic capacity than the Nd:YAG laser.

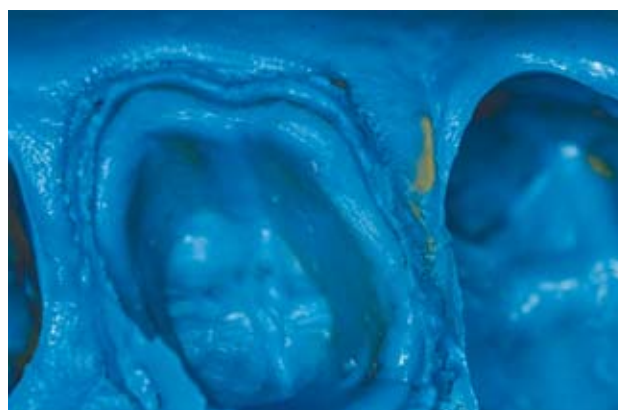

Fig 7 Electrosurgery technique: impression taking (female, 47 years old, anterior dental arch).

REFERENCES

1. Martignoni M, Shoneberg A. Precisione e contorno nella ricostruzione protesica. Berlino: Quintessenza Biblioteca, 1987.
2. Maynard JG, Weilson RD. Physiologic dimensions of the periodontium significant to restorative dentist. J Periodontol 1979; 50:170-174.
3. Stetler KJ, Bissada NF. Significance of the width of keratinized gingiva on the periodontal status of teeth with submarginal restorations. J Periodontol 1987;58:696-700.
4. Ruell J, Schuessler PJ, Malament K, Mori D. Effects of retraction procedures on the periodontium in humans. J Prosthet Dent 1980;44:508-515.
5. Valderhaug J, Birkeland JM. Periodontal conditions in patient 5 years following insertion of fixed prostheses. Pocket depth and loss of attachment. J Oral Rehabil 1976;3:237-243.
6. Cohelo DH, Cavallaro J. Gingival recession with electrosurgery for impression making. J Prosthet Dent 1975;33:422-426.
7. Abdel Gabbar F, Aboulazm SF. Comparative study on gingival retraction using mechanochemical procedure and pulsed Nd:YAG laser irradiation. Egypt Dent J 1995;41:1001-1006.
8. Myers TD, Myers WD, Stone RM. First soft tissue study utilizing a pulsed Nd:YAG dental laser. Northwest Dent 1989;68:14-17.
9. Romanos G, Nentwig GH. Diode laser (980 nm) in oral and maxillofacial surgical procedures: clinical observations based on clinical applications. J Clin Laser Med Surg 1999;17:193-197.
10. Romanos G, Nentwig GH. Present and future of lasers in oral soft tissue surgery: clinical applications. J Clin Laser Med Surg 1996;14:179-184.
11. Goharkhay K, Moritz A, Wilder-Smith P, Schooop U, Kluger W, Jakolitsch S, Sperr W. Effects on oral soft tissue produced by a diode laser in vitro. Lasers Surg Med 1999;25:401-406.
12. Loe H. The Gingival Index, the Plaque Index and the Retention Index system. J Periodontol 1967;38:610-619.
13. Ainamo J, Barmes D, Beagrie G, Cutress T, Marin J, Sardo-Infirri J. Development of the World Health Organization (WHO) community periodontal index of treatment needs (CPITN). Int Dent J 1982;32:281-291.
14. Pameijer CH. A one-step putty-wash impression technique. J Prosthet Dent 1990;64:635-636.
15. Nissan J, Laufer BZ, Brosh T, Assif D. Accuracy of three polyvinyl siloxane putty-wash impression techniques. J Prosthet Dent 2000;83:161-165.
16. Cloyd S, Puri S. Using the double-cord packing technique of tissue retraction for making crown impression. Dent Today 1999;18:54-59.
17. Jokstad A. Clinical trial of gingival retraction cords. J Prosthet Dent 1999;81:258-261.
18. Coelho DH, Cavallaro J, Rothschild EA. Gingival recession with electrosurgery for impression making. J Prosthet Dent 1975; 33:422-426.
19. Sherman JA. Enhanced impression technique with radiosurgery. Dent Today 1998;17:100-103.

Contact address: Dott. Francesca Cattoni, Department of Dentistry, Vita.Salute University, San Raffaele Hospital, Via Olgettina, 48; I-20132 Milan, Italy. Tel: +39-02-26432970, Fax: +39-02-26432953. e-mail: cattonif@tiscalinet.it

Clinical Investigations of Medical Devices in Dentistry

Specification, Interpretation, and Practical Guidance



*Martin Groten,
Ralf Janda,
and Mark Latta*

There is a tremendous need for guidance among those involved in the development of dental products, with their complex clinical requirements based on chemical, physical, biological, functional, and esthetic properties. This book offers a systematic approach to fulfilling the legal and medical requirements for testing materials and devices in both Europe and the United States. It also gives detailed instructions on how to conduct studies, report findings, and handle problems.

Contents

- Introduction and Definitions
- Legal Requirements and Applicable Regulatory Requirements
- Preparatory Steps
- The Conception of Clinical Studies
- The Practice of Clinical Studies
- Monitoring
- Final Report

176 pp (softcover)

ISBN 1-85097-069-6; US \$50/£31/€42

To Order

Call: +44 (0) 20 8949 6087

Fax: +44 (0) 20 8336 1484

Website: www.quintpub.co.uk

E-mail: info@quintpub.co.uk



Quintessence Publishing Co Ltd